

Catheter ablation of typical and atypical atrial flutters in a patient with transcatheter tricuspid valve replacement

Eric D. Braunstein, MD, Sumeet S. Chugh, MD, FHRS, Raj R. Makkar, MD, Ashkan Eghaie, MD, FHRS, Michael Shehata, MD, FHRS, Xunzhang Wang, MD

From the Department of Cardiology, Smidt Heart Institute, Cedars-Sinai, Los Angeles, California.

Introduction

Tricuspid regurgitation (TR) is a common form of valvular heart disease and has been associated with adverse outcomes including heart failure and an increased risk of mortality.¹ This may be particularly true in patients with coexisting atrial arrhythmias.^{2,3} Surgical management of isolated TR has traditionally been avoided owing to relatively high surgical risk.⁴ Recently, transcatheter tricuspid valve replacement (TTVR) using the EVOQUE system has shown promise as a safe and effective treatment for patients with severe TR.⁵ While TTVR remains experimental, published short- and medium-term outcomes suggest potential for benefit from this procedure.^{6,7}

Atrial fibrillation (AF) and flutter (AFL) commonly coexist with TR, and either disease can perpetuate the other. Primary or idiopathic TR may lead to right atrial (RA) dilation and precipitate AF⁸ or AFL,⁹ while secondary TR may result from RA dilation caused by atrial arrhythmias.¹⁰ As minimally invasive management of TR becomes safer and more effective, the number of patients with a TTVR who also require invasive management of atrial arrhythmias will likely increase.

Successful ablation of cavotricuspid isthmus (CTI)-dependent AFL has previously been described in patients with surgical tricuspid valve replacements.¹¹ There has also been description of catheter ablation after other transcatheter valve procedures, including transcatheter aortic valve replacement.¹² To our knowledge there are no reports of catheter ablation in a patient with a TTVR.

KEYWORDS Catheter ablation; Atrial flutter; Tricuspid regurgitation; Transcatheter tricuspid valve replacement; Cavotricuspid isthmus (Heart Rhythm Case Reports 2022; ■:1–4)

Funding Sources: There were no funding sources for this work. **Disclosures:** The authors have no relevant financial disclosures or conflicts of interest. **Address reprint requests and correspondence:** Dr Eric D. Braunstein, Cedars-Sinai Smidt Heart Institute, 127 S. San Vicente Blvd, Suite A3600, Los Angeles, CA 90048. E-mail address: Eric.Braunstein@cshs.org.

KEY TEACHING POINTS

- Careful assessment for atrial arrhythmias, particularly typical atrial flutter, may be advisable before transcatheter tricuspid valve replacement (TTVR), since durable cavotricuspid isthmus (CTI) block could be challenging after TTVR.
- Coronary sinus (CS) cannulation and CS catheter stability may be challenging after TTVR, which may be owing to anatomic distortion in this area from the TTVR valve.
- When performing transseptal puncture after TTVR, a high and posterior transseptal catheterization location may be preferable to avoid interaction with the TTVR valve.
- Catheter ablation after TTVR need not be avoided, but careful procedural planning should be pursued, with a strong consideration for the use of intracardiac echo, particularly for CTI ablation.

Case report

This is a case of a 71-year-old woman with a history notable for paroxysmal AF and AFL, tachycardia-bradycardia and sick sinus syndrome status post a dual-chamber pacemaker, heart failure with preserved ejection fraction, and severe TR, who had undergone TTVR with an EVOQUE 48 mm valve 3 weeks prior to presentation to the hospital with tachycardia and fatigue. Device interrogation revealed an increasing burden of atrial arrhythmias over a period of months both before and after TTVR, and at the time of presentation she was in persistent atrial flutter with cycle length (CL) ~400 ms. Ventricular response was controlled at baseline but tachycardia to the 150s with associated symptoms of palpitations was observed with light activity.

She had undergone several prior radiofrequency (RF) catheter ablations for AF and AFL, which involved

pulmonary vein isolation, posterior wall isolation, CTI ablation, and an anterior mitral line (mitral annulus to the right superior pulmonary vein) for treatment of perimitral flutter. Medically, she had been managed with flecainide and low-dose beta-blockers.

Given persistent slow atrial flutter, flecainide was discontinued. Over the following days the atrial CL was seen to decrease to ~ 350 ms, followed by disorganization to persistent AF. Given continued symptomatic arrhythmias, the decision was made to perform repeat RF catheter ablation.

The patient was brought to the electrophysiology laboratory and the procedure performed under deep sedation. The CARTO3 system (Biosense Webster, Inc, Irvine, CA) was used for electroanatomic mapping. Vascular access was obtained via the right femoral vein. An intracardiac echo (ICE) probe was placed, and a baseline ICE exam was performed; the TTVR valve was well visualized on ICE, and ICE contours of the TTVR valve and CTI were obtained on the electroanatomic mapping system (Figure 1). A decapolar mapping catheter (DecaNav; Biosense Webster, Inc, Irvine, CA) was placed through a fixed-curve (SR0) sheath after difficulty cannulating the coronary sinus (CS) without a sheath was observed, and was placed partially into a posterolateral ventricular CS branch to optimize stability.

A single transseptal puncture was performed using a BRK-1 needle through a deflectable sheath (ViziGo; Biosense Webster, Inc, Irvine, CA) under ICE, electroanatomic mapping, pressure, and fluoroscopic guidance. The puncture was performed in a high and posterior location in order to avoid any interaction with the TTVR valve. Heparin was given during the procedure to maintain an activated clotting time of 300–350 seconds.

The patient's presenting rhythm in the lab was AF, and after transseptal puncture a 200 J DC cardioversion was performed with successful return to the patient's baseline sinus bradycardia. A mapping catheter (PentaRay; Biosense Webster, Inc, Irvine, CA) was advanced to the left atrium (LA), and electroanatomic mapping of the LA was performed

during CS pacing. This showed that the pulmonary veins and posterior wall were isolated from the prior procedures. There was evidence of a prior anterior mitral line, but this line did not appear blocked based on differential pacing. Based on voltage mapping there was evidence of left atrial myopathy in the LA anterior wall and floor.

Arrhythmia induction was performed with atrial burst pacing, and atrial tachycardia/flutter was induced with CL 340 ms and concentric CS activation. Electroanatomic mapping and entrainment during tachycardia showed counterclockwise perimitral flutter. A practical isthmus was identified along the upper portion of the previously ablated anterior mitral line near the right superior pulmonary vein. A cluster of RF ablation using a force-sensing irrigated 3.5 mm catheter (ThermoCool ST SF; Biosense Webster, Inc, Irvine, CA) was performed in this area with slowing and termination of tachycardia following the first lesion. Subsequently, a second atrial tachycardia was induced with CL 340 ms. LA and RA activation mapping and entrainment was performed and showed a biatrial flutter involving the mitral annulus, with breakthrough across the anterior mitral line and into the RA across the Bachmann bundle. Additional ablation was performed at the earliest site in the RA (presumed Bachmann bundle insertion) with slowing and termination of tachycardia following the first lesion. Additional ablation was performed around this site and along the RA septum anatomically opposite to the previous lesions in the LA. Mapping after ablation was completed showed the anterior mitral line had bidirectional block with a transit time of 180 ms.

At this point, the previously ablated CTI line was assessed and was observed to be incomplete with a trans-isthmus time of ~ 100 ms; mapping suggested breakthrough in the mid-CTI. Using ICE and electroanatomic mapping guidance, point-by-point ablation was performed starting in the mid-CTI at the area of apparent breakthrough to the inferior vena cava. After initial ablation, repeat mapping revealed that breakthrough was closer to the tricuspid annulus/TTVR valve. When the catheter was positioned as distally

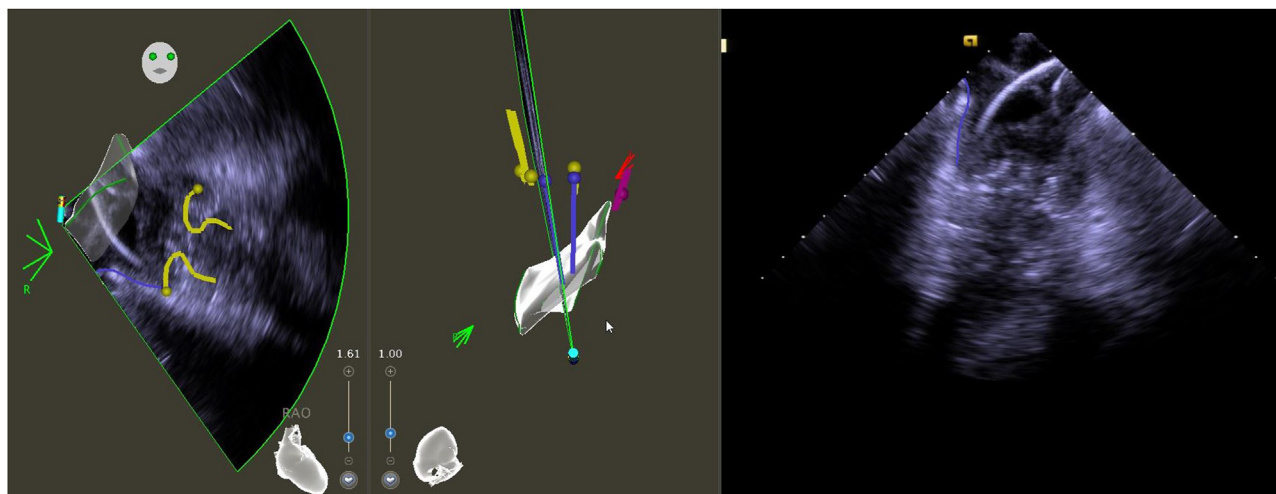


Figure 1 Intracardiac echo images of the EVOQUE transcatheter tricuspid valve replacement (TTVR) valve and cavotricuspid isthmus (CTI), with electroanatomic mapping system contours of the TTVR (yellow) and CTI (purple) in right anterior oblique (RAO) and left anterior oblique caudal views.

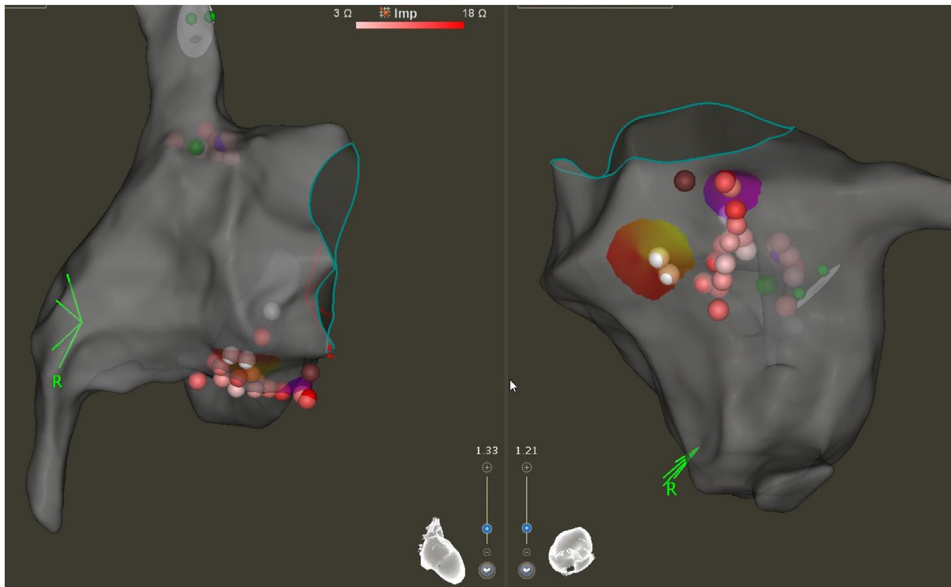


Figure 2 Cavotricuspid isthmus (CTI) ablation lesion set in right anterior oblique and left anterior oblique caudal views. Several long-duration lesions were required on the tricuspid annular end of the line in order to achieve durable block.

along the CTI as possible, contact with the TTVR valve struts was observed on ICE, and concurrently system impedance dropped to ~ 40 ohms. At this position an atrial electrogram, with no ventricular electrogram, was observed. The catheter was pulled back slightly and deflected until the impedance returned to baseline (80–100 ohms), and RF ablation was performed. After ~ 20 seconds of ablation at 35 W, CTI block was achieved. Additional lesions were delivered at and near this position given the delayed time to CTI block during ablation (Figure 2). After ablation was completed, bidirectional CTI block was seen with a trans-isthmus time of >150 ms, including after a waiting period.

Arrhythmia induction was repeated using atrial burst pacing and no arrhythmias were inducible following a waiting period of 20 minutes. ICE and fluoroscopy demonstrated no apparent changes in TTVR valve position or function. The catheters and sheaths were removed.

Postprocedurally, the patient recovered well, without complications. She was started on sotalol for prevention of AF. She was subsequently discharged home and has not had recurrent atrial arrhythmias in follow-up at 30 days. A postprocedural transthoracic echocardiogram showed normal function of the TTVR valve.

Discussion

This case reports demonstrates the ability to perform safe and effective catheter ablation in a patient with a TTVR, while also highlighting potential challenges that may be encountered in these patients.

The most notable challenge in this patient was with CTI ablation owing to the presence of the TTVR valve in the tricuspid annulus. This patient had undergone prior CTI ablation; and while there was evidence of prior ablation along the

CTI, it was not blocked. When the catheter was positioned along the CTI as proximate to the tricuspid annulus as possible, contact with the TTVR valve struts was seen on ICE and accompanied by a large decrease in system impedance. In this position, only atrial electrograms were observed, and positioning at the typical starting position for CTI ablation with a large ventricular and small atrial electrogram was not possible.¹³ TTVR valve position relative to the native tricuspid annulus may be variable from patient to patient, depending on the anatomy of the tricuspid subvalvular apparatus, and generally the valve is positioned as close to the atrium as possible.⁵ In this patient, durable CTI block was achieved with several longer-duration lesions adjacent to the TTVR valve, but it is possible block was achieved in combination with prior ablation along the CTI before the TTVR was performed. Careful assessment for atrial arrhythmias, particularly typical atrial flutter, may be advisable before TTVR, since durable CTI block could be challenging after TTVR. However, additional clinical experience and investigation will be helpful in this regard.

CS cannulation and CS catheter stability was also a challenge in this case, which may have been due to anatomic distortion in this area from the TTVR valve. With assistance from a fixed-curve sheath,¹⁴ the CS could be cannulated, and by advancing the catheter relatively deep into a posterolateral ventricular CS branch the catheter was able to be secured in a stable position, allowing for use of the CS as a mapping reference.

In this first case we were careful to avoid interaction with the TTVR during transseptal catheterization, which was achieved by positioning the puncture high and posterior, away from the tricuspid annulus. This is similar to approaches that have been described after surgical tricuspid valve repair.¹⁵

In conclusion, in our case safe and effective ablation of both typical and atypical atrial flutters was achieved following TTVR. This report suggests that catheter ablation after TTVR need not be avoided, but that careful procedural planning should be pursued, with a strong consideration for the use of intracardiac echo, particularly for CTI ablation.

References

1. Topilsky Y, Nkomo VT, Vatury O, et al. Clinical outcome of isolated tricuspid regurgitation. *JACC Cardiovasc Imaging* 2014;7:1185–1194.
2. Prapan N, Ratanasit N, Karaketklang K. Significant functional tricuspid regurgitation portends poor outcomes in patients with atrial fibrillation and preserved left ventricular ejection fraction. *BMC Cardiovasc Disord* 2020;20:1–8.
3. Takahashi Y, Izumi C, Miyake M, et al. Actual management and prognosis of severe isolated tricuspid regurgitation associated with atrial fibrillation without structural heart disease. *Int J Cardiol* 2017;243:251–257.
4. Condello F, Gitto M, Stefanini GG. Etiology, epidemiology, pathophysiology and management of tricuspid regurgitation: an overview. *Rev Cardiovasc Med* 2021;22:1115–1142.
5. Fam NP, von Bardeleben RS, Hensey M, et al. Transfemoral transcatheter tricuspid valve replacement with the EVOQUE system: a multicenter, observational, first-in-human experience. *JACC Cardiovasc Interv* 2021;14:501–511.
6. Kodali S, Hahn RT, George I, et al. Transfemoral tricuspid valve replacement in patients with tricuspid regurgitation: TRISCEND study 30-day results. *JACC Cardiovasc Interv* 2022;15:471–480.
7. Webb JG, Chuang A, Ming yu, Meier D, et al. Transcatheter tricuspid valve replacement with the EVOQUE system: 1-year outcomes of a multicenter, first-in-human experience. *JACC Cardiovasc Interv* 2022;15:481–491.
8. Rahman F, Wang N, Yin X, et al. Atrial flutter: clinical risk factors and adverse outcomes in the Framingham Heart Study. *Heart Rhythm* 2016;13:233–240.
9. Tai CT, Chen SA. Conduction barriers of atrial flutter: relation to the anatomy. *Pacing Clin Electrophysiol* 2008;31:1335–1342.
10. Zhou X, Otsuji Y, Yoshifuku S, et al. Impact of atrial fibrillation on tricuspid and mitral annular dilatation and valvular regurgitation. *Circ J* 2002;66:913–916.
11. Goto E, Nakamura K, Sasaki T, Naito S. Successful ablation of cavotricuspid isthmus-dependent atrial flutter guided by contact force vector in a patient after a tricuspid valve replacement. *Indian Pacing Electrophysiol J* 2014;14:306–308.
12. Ammar A, Elbatran AI, Wijesuriya N, Saberwal B, Ahsan SY. Management of atrial fibrillation after transcatheter aortic valve replacement: challenges and therapeutic considerations. *Trends Cardiovasc Med* 2021;31:361–367.
13. Poty H, Saoudi N, Nair M, Anselme F, Letac B. Radiofrequency catheter ablation of atrial flutter. *Circulation* 1996;94:3204–3213.
14. Pepper CB, Davidson NC, Ross DL. Use of a long preshaped sheath to facilitate cannulation of the coronary sinus at electrophysiologic study. *J Cardiovasc Electrophysiol* 2001;12:1335–1337.
15. Lewalter T, Jung W, Preusse CJ, et al. Radiofrequency catheter ablation of an incessant ventricular tachycardia following valve surgery. *Pacing Clin Electrophysiol* 2002;25:105–108.